



PATIENT

Violet Morris

PRESENTING CLINICAL SIGNS

History: Cough. Lethargy. Grade 2/3 murmur.

SPECIES

Canine

BREED

Golden Retriever

SEX

Female Spayed

ECHOCARDIOGRAM FINDINGS

2D, m-mode, color flow and doppler imaging is available. Marked left ventricular dilation with diminished systolic function and increased sphericity. Decreased LV wall thickness. Increased EPSS. Severe left atrial enlargement. The mitral valve appears mildly thickened, with no obvious prolapse into the left atrial lumen. The systolic dysfunction is mildly asymmetric with an akinetic free wall compared to a hypokinetic septum. Moderate central mitral regurgitation. Normal velocity. Tricuspid valve appears normal in form and function. Mild right atrial and ventricular dilation. Moderate tricuspid regurgitation. Velocity consistent with mild to moderate. The aortic valve is normal in morphology and mobility. Decreased LVOT velocities. No aortic or pulmonic insufficiency. No pericardial or pleural effusion noted. No obvious cardiac tumors.

CARDIAC CHART

AGE

7 years

WEIGHT

72.8lbs

INTERPRETED BY

Maggie Machen Lamy,
DVM, DACVIM
(Cardiology)

IMAGING PERFORMED BY

Dave Stasiuk,
RDMS, RDCS

HOSPITAL NAME

Southpointe Pet
Hospital

REFERRING VET

NP

INVOICE

23174

DATE

3/17/22

CANINE CARDIAC PARAMETERS	MR VMAX (m/s)	TR VMAX (m/s)	LA/AO (Boon method)	LA/AO (Heart Base; Swe)	FS (%)	EF (%)	EPSS (cm)
NORMAL PARAMETER	4.5-5.5	<2.7	1.3	<1.6	28-40	40-100	<0.6
PATIENT		3.3	1.8	2.8	11	28	2.7
CANINE CARDIAC PARAMETERS	HR (BPM)	AV VMAX (m/s)	PV MAX (m/s)	BODY WEIGHT (kg)	LA 2D short axis Base view (cm)	LVIDd Avg; 2D and m-mode short axis (cm)	LVIDs Avg; 2D and m-mode short axis (cm)
NORMAL PARAMETER	50-100	0.7-1.7	0.7-1.6	BELOW	BELOW	BELOW	BELOW
PATIENT	NM	0.7	nm	33.0	4.7	8.1	7.2
*Normal chamber parameters expressed as a mean value (SD)				3	1.27 (5.3)	2.46 (2.46)	1.36 (5.5)
BODY WEIGHT DEPENDENT PARAMETERS				5	1.40 (4.5)	2.74 (5.2)	1.60 (4.7)
<i>*Note: All measurements based upon multi-modal images and methods. An average value is reported.</i>				10	1.50 (3.8)	3.27 (3.5)	2.06 (3.1)
				15	1.83 (2.0)	3.71 (2.4)	2.43 (2.1)
				20	2.02 (1.9)	4.14 (2.2)	2.80 (2.0)
Adapted from June Boon, Veterinary Echocardiography, 1998				25	2.18 (2.4)	4.48 (2.9)	3.10 (2.5)
Rishniw M and Hollis NE, J Vet Intern Med 2000; 14:429-435				30	2.33 (3.3)	4.83 (3.9)	3.39 (3.4)
Hansson et al, Vet Rad and Ultrasound 2002				35	2.48 (4.3)	5.17 (5.0)	3.69 (4.5)
Bonagura et al. Echocardiography: principles of interpretation, Vet Clin North Am 15:1177, 1995				40	2.62 (5.2)	5.48 (6.1)	3.96 (5.4)
				50	2.88 (7.1)	6.07 (8.3)	4.46 (7.4)

INTERPRETATION OF THE FINDINGS & FURTHER RECOMMENDATIONS

Unfortunately, this patient has significant cardiomyopathy and systolic dysfunction. This is causing dilation and volume overload of both the left and right heart. Moderate MR and TR are noted, which is suspected to be secondary to annular stretch; early concurrent CVD cannot be ruled out. Mild to moderate pulmonary hypertension is noted, which is likely due to early congestion. Regardless, the severity of dysfunction and pump failure is significant, and the patient is at high risk for decompensating into congestive failure. Patient will always be at risk for right and/or left-sided CHF, development of arrhythmias/syncope and/or sudden death going forward.

Systolic failure can be primary in nature (DCM) or secondary to taurine deficiency, myocarditis, tachycardia-induced cardiomyopathy, thyroid disease, or infiltrative disease such as lymphoma. In



PATIENT

Violet Morris

SPECIES

Canine

BREED

Golden Retriever

SEX

Female Spayed

AGE

7 years

WEIGHT

72.8lbs

INTERPRETED BY

Maggie Machen Lamy,
DVM, DACVIM
(Cardiology)

IMAGING PERFORMED BY

Dave Stasiuk,
RDMS, RDCS

HOSPITAL NAME

Southpointe Pet
Hospital

REFERRING VET

NP

INVOICE

23174

DATE

3/17/22

a relatively young atypical breed (uncommon signalment for DCM), consider testing for primary causes that may be treatable. A troponin (cTnI) level can be submitted to further investigate infiltrative/inflammatory contribution (myocarditis). Additionally, a taurine level may be helpful (screen for malabsorption issue), and a thorough diet history given the recent correlation with grain free/boutique brand/exotic ingredient diets. Finally, further systemic evaluation for underlying infiltrative contribution such as neoplasia is also reasonable (abdominal ultrasound, etc.). Regardless of cause, prognosis is poor at this stage in the disease process, with an average survival time of <6 months. The only treatable cause of systolic failure is diet/taurine deficiency, which is uncommon on commercially formulated dog foods. If the diet is of concern, highly recommend immediate diet change and taurine supplement regardless of blood taurine results. Please see the FDA website for more information.

The respiratory signs are concerning for imminent CHF and immediate institution of full cardiac supportive medications is recommended as below due. If the breathing worsens or the patient appears unstable, consider hospitalization for stabilization. Cases of systolic failure are at high risk for malignant tachyarrhythmias (such as VT or rapid AF) and sudden death, and this should be expressed to the owner. Activity restriction is advised, and a baseline ECG recommended.

Elective anesthesia is not advised due to exceedingly high risk for complications.

Omega fatty acid supplementation and mild salt restriction may be of some long-term benefit. Monitor for development of a cough, worsening labored breathing, abdominal distention, exercise intolerance or collapse episodes in the future. Monitoring of sleeping breathing rates at home is recommended to assess response to medications and recurrence of CHF in the future.

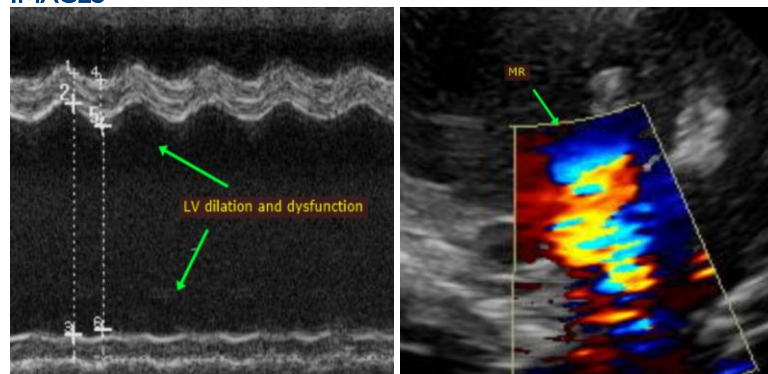
PLAN:

Baseline BP, ECG and CXR are recommended. Initiate aldosterone antagonist Spironolactone 1-2mg/kg PO q12h. Institute furosemide 1-2mg/kg PO q12h. Institute Pimobendan 0.3mg/kg PO q12h. Institute taurine 1000mg PO q12h. Diet history/change as discussed.

Monitor a renal panel and blood pressure in 1-2 weeks to ensure tolerance. If BP >130mmHg, institute ACEI 0.5mg/kg PO q12h. Consider cTnI, taurine level, AUS as discussed above.

A recheck echocardiogram is recommended in 6 months to screen for progression, sooner if clinical issues arise in the interim.

IMAGES





PATIENT

Violet Morris

SPECIES

Canine

BREED

Golden Retriever

SEX

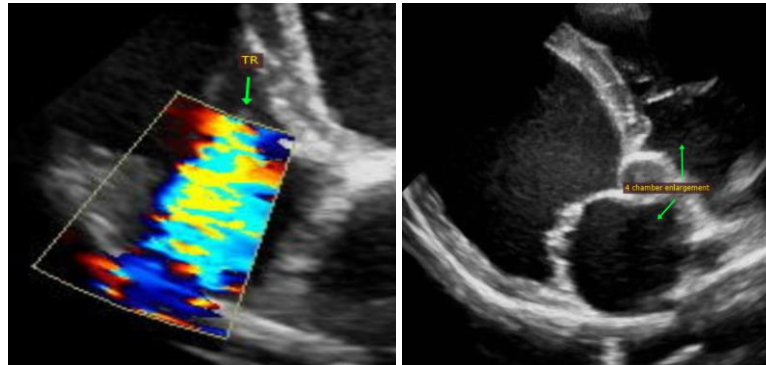
Female Spayed

AGE

7 years

WEIGHT

72.8lbs



The information and recommendations provided are based on the images presented by the referring veterinarian. No evaluation can be communicated regarding pathology that was not visible in the image/video clips provided.

Thank you for this referral. This report was generated using transcription software, and minor dictation errors may be present. If the clinical or image interpretation does not parallel your findings or if I can be of any further assistance, please contact me.

Maggie Machen Lamy, DVM
Diplomate of the American College of Veterinary Internal Medicine (Cardiology)
info@sonopath.com

INTERPRETED BY

Maggie Machen Lamy,
DVM, DACVIM
(Cardiology)

IMAGING PERFORMED BY

Dave Stasiuk,
RDMS, RDCS

HOSPITAL NAME

Southpointe Pet
Hospital

REFERRING VET

NP

INVOICE

23174

DATE

3/17/22